



PATIENT

Jackson Erspamer

SPECIES

Canine

BREED

Labrador Retriever

SEX

Male Neutered

AGE

9 years

WEIGHT

50lbs

INTERPRETED BY

Maggie Machen
Lamy, DVM, DACVIM
(Cardiology)

IMAGING PERFORMED BY

Kim Liedberg

HOSPITAL NAME

SVS Imaging

REFERRING VET

Dr. Dowling

INVOICE

21253

DATE

9/28/21

PRESENTING CLINICAL SIGNS

History: About 3 months ago Jackson had a tooth extracted. He had a decrease of appetited and was put on antibiotics. He continued to have a decreased appetite. Chest rads and abdominal radiographs taken and noted defused pulmonary nodules in the lung field.

-Abnormal PE/Chem/CBC/UA Results: Blasto was normal, BW: NSF.

RADIOGRAPHIC FINDINGS *NOTE: Images submitted for supplemental cardiac information only.

Normal cardiac silhouette. No obvious evidence of CHF. Diffuse nodular pattern most consistent with metastatic disease.

ECHOCARDIOGRAM FINDINGS

2D, m-mode, color flow and doppler imaging is available. Normal mitral valve leaflets with no prolapse into the left atrial lumen. No obvious mitral regurgitation with a normal left atrial dimension. Normal LV diameter with adequate myocardial function. The tricuspid valve appears mildly thickened with mild tricuspid regurgitation. Normal TR velocity. Normal right atrial and ventricular diameter and morphology indicating no overt evidence of pulmonary arterial hypertension. The pulmonic and aortic valves are normal in morphology and mobility. Normal pulmonic and aortic outflow velocities with laminar flow. No obvious aortic or pulmonic insufficiency. No pericardial or pleural effusion noted. No obvious cardiac masses.

CARDIAC CHART

CANINE CARDIAC PARAMETERS	MR VMAX (m/s)	TR VMAX (m/s)	LA/AO (Boon method)	LA/AO (Heart Base; Swe)	FS (%)	EF (%)	EPSS (cm)
NORMAL PARAMETER	4.5-5.5	<2.7	1.3	<1.6	28-40	40-100	<0.6
PATIENT	NA	2.0	NM	1.2	30	58	0.8
CANINE CARDIAC PARAMETERS	HR (BPM)	AV VMAX (m/s)	PV MAX (m/s)	BODY WEIGHT (kg)	LA 2D short axis Base view (cm)	LVIDd Avg; 2D and m-mode short axis (cm)	LVIDs Avg; 2D and m-mode short axis (cm)
NORMAL PARAMETER	50-100	0.7-1.7	0.7-1.6	BELOW	BELOW	BELOW	BELOW
PATIENT	140	0.98	0.7	22.7	2.7	4.2	2.9
*Normal chamber parameters expressed as a mean value (SD)				3	1.27 (5.3)	2.46 (2.46)	1.36 (5.5)
BODY WEIGHT DEPENDENT PARAMETERS				5	1.40 (4.5)	2.74 (5.2)	1.60 (4.7)
<i>*Note: All measurements based upon multi-modal images and methods. An average value is reported.</i>				10	1.50 (3.8)	3.27 (3.5)	2.06 (3.1)
				15	1.83 (2.0)	3.71 (2.4)	2.43 (2.1)
				20	2.02 (1.9)	4.14 (2.2)	2.80 (2.0)
				25	2.18 (2.4)	4.48 (2.9)	3.10 (2.5)
				30	2.33 (3.3)	4.83 (3.9)	3.39 (3.4)
				35	2.48 (4.3)	5.17 (5.0)	3.69 (4.5)
				40	2.62 (5.2)	5.48 (6.1)	3.96 (5.4)
				50	2.88 (7.1)	6.07 (8.3)	4.46 (7.4)

Adapted from June Boon, Veterinary Echocardiography, 1998
Rishniw M and Hollis NE, J Vet Intern Med 2000; 14:429-435
Hansson et al, Vet Rad and Ultrasound 2002
Bonagura et al. Echocardiography: principles of interpretation, Vet Clin North Am 15:1177, 1995



PATIENT

Jackson Erspamer

SPECIES

Canine

BREED

Labrador Retriever

SEX

Male Neutered

AGE

9 years

WEIGHT

50lbs

INTERPRETED BY

Maggie Machen Lamy, DVM, DACVIM
(Cardiology)

IMAGING PERFORMED BY

Kim Liedberg

HOSPITAL NAME

SVS Imaging

REFERRING VET

Dr. Dowling

INVOICE

21253

DATE

9/28/21

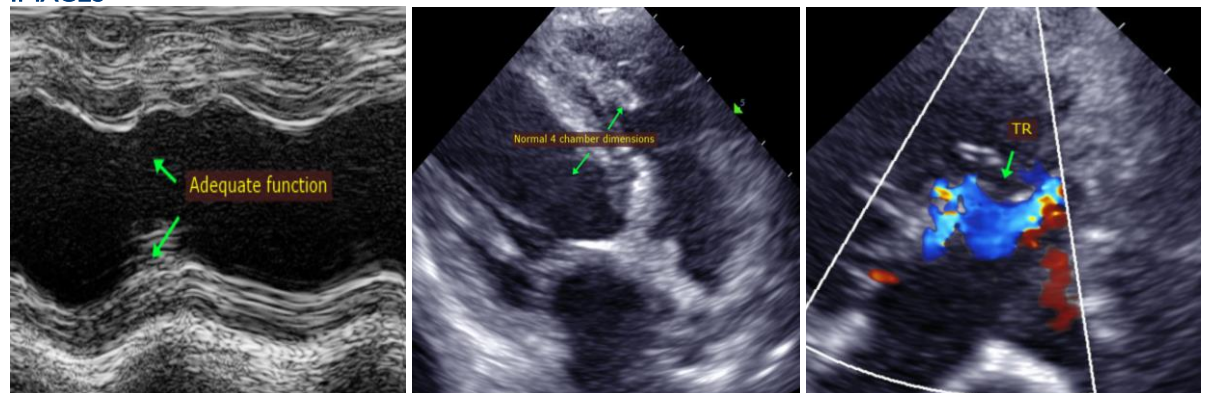
INTERPRETATION OF THE FINDINGS & FURTHER RECOMMENDATIONS

Overtly normal cardiac dimensions and function, with no obvious dysfunction or dilation of the left heart. A small tricuspid leak is noted which is likely physiologic in origin. No other significant valvular leaks are visualized, and no evidence of pulmonary hypertension. No obvious intra or extra-cardiac tumors are identified; however, it is important to note these are easily missed in the absence of effusion.

Monitor for development of a heart murmur, cough, labored breathing, exercise intolerance or collapse episodes.

A recheck echocardiogram is recommended should a significant murmur develop, or signs of cardiac compromise be noted in the future.

IMAGES



The information and recommendations provided are based on the images presented by the referring veterinarian. No evaluation can be communicated regarding pathology that was not visible in the image/video clips provided.

Thank you for this referral. This report was generated using transcription software, and minor dictation errors may be present. If the clinical or image interpretation does not parallel your findings or if I can be of any further assistance, please contact me.

Maggie Machen Lamy, DVM
Diplomate of the American College of Veterinary Internal Medicine (Cardiology)
info@sonopath.com